

EXPERT PANEL REPORT

Consensus round table meeting: Clinical pathway for using topical oxygen therapy in practice



Wounds UK

PUBLISHED BY:

Wounds UK
1.01 Cargo Works
1-2 Hatfields
London SE1 9PG, UK
Tel: + 44 (0)20 7627 1510
Fax: +44 (0)20 7627 1570
www.wounds-uk.com

Wounds UK

© Wounds UK 2017

This document has been developed by Wounds UK and supported by Inotec AMD Ltd

The views expressed are those of the authors and do not necessarily reflect those of Inotec AMD Ltd

How to cite this document:

Wounds UK Expert Panel Report. *Consensus round table meeting: Clinical pathway for using topical oxygen therapy in practice*. London: Wounds UK, 2017. Available to download from: www.wounds-uk.com

FOREWORD

The role of oxygen in wound healing is well documented, and emerging research suggests that improved methods of delivery may now make topical oxygen therapy a more viable and practical treatment (Harding, 2016). This document discusses the use of topical oxygen therapy in practice and how it may aid healing in a range of wounds, focusing on the new topical oxygen therapy product NATROX® (Inotec AMD Ltd).

NATROX is a portable medical device, which enables clinicians to apply oxygen directly to a wound to assist healing in chronic or previously non-healing wounds. Preliminary experience in using the device, particularly in diabetic foot ulcers, has been promising. Furthermore, the studies have demonstrated that the device has high levels of patient acceptability, which may help to promote compliance and facilitate topical oxygen therapy more effectively than previous methods of therapy.

A group of experts met in December 2016 to discuss the clinical implications of this method of delivering topical oxygen therapy and set out to:

- Agree how and when to use NATROX
- Consider the experience gathered using NATROX in diabetic foot ulcers to inform wider indications for use
- Agree a treatment pathway
- Explore the potential impact of oxygen therapy on wound healing and patient quality of life.

The goal of this document is to provide clinicians with the information they need to select and use NATROX topical oxygen therapy appropriately in practice.

EXPERT WORKING GROUP

Chair: Keith Harding Dean of Clinical Innovation, Cardiff University; Medical Director, Welsh Wound Innovation Centre, Cardiff, UK

Simon Barrett Tissue Viability Lead, Humber NHS Foundation Trust, East Riding of Yorkshire, UK

Paul Chadwick Consultant Podiatrist, Salford Royal NHS Foundation Trust, Salford, UK

Jacqui Fletcher Independent Nurse Consultant, UK

Sarah Gardner Clinical Lead for Tissue Viability, Oxford Health NHS Foundation Trust, Oxford, UK

Nicky Ivins Clinical Research Director, Welsh Wound Innovation Centre; Cardiff University, Cardiff, UK

Joanne McCardle Diabetes Foot Clinical Research Fellow, NHS Lothian, Edinburgh, UK

Duncan Stang Podiatrist; National Diabetes Foot Coordinator for Scotland, UK

The history of oxygen therapy in wound healing

The critical role of oxygen in wound healing has been well documented and oxygen has long been used as a wound therapy.

HYPERBARIC OXYGEN

Hyperbaric oxygen therapy was first used in the 1930s to treat divers suffering from 'the bends' (Yarbrough and Benke, 1939). The therapy was further developed to support patients undergoing cardiac surgery (Boerema et al, 1956), and to treat clostridial gas gangrene (Brummelkamp et al, 1961) and carbon monoxide poisoning (Smith and Sharp, 1962).

Hyperbaric oxygen therapy was first used in the field of wound care following the discovery in 1965 that patients with burns who received the treatment for carbon monoxide poisoning healed more quickly (Wada et al, 1965). The association between oxygen and wound healing has since been investigated further and applied to a range of wounds.

The term 'hyperbaric' means 'higher pressure' and hyperbaric oxygen therapy is delivered in a high-pressure chamber. This creates limitations to its use in clinical practice due to logistical and financial constraints. Hyperbaric oxygen chambers are not portable, and therefore cannot be used for supplying continuous oxygen therapy to the patient in a community or home environment. Consequently, using a hyperbaric oxygen chamber is lifestyle-limiting for the patient and treatment is delivered in short bursts. This means that the oxygen levels in the wound are raised for only a small percentage (typically 4.5–6%) of a week (Winfeld, 2014).

LOCALISED TOPICAL OXYGEN

More recently, therefore, more localised methods of oxygen delivery have been investigated, such as large pressurised cylinders of oxygen connected to a chamber or bag that surrounds the anatomical region of the wound. This represented a step forward, but still required cumbersome specialist units which restricted patients' mobility and lifestyle during treatment and limited the practicality of delivering treatment. However, it was found that topical oxygen therapy was a useful development and improved healing without the need for full-body hyperbaric chambers (Tawfick and Sultan, 2009).

AMBULATORY TOPICAL OXYGEN

NATROX represents a new development in topical oxygen therapy, as it provides a more practical and patient-friendly mode of delivery for oxygen therapy. It is lightweight, small (approximately the size of a mobile phone) and portable, and can provide continuous oxygen therapy. It is suitable for wearing under clothes during the day, and can be positioned to be used comfortably at night, facilitating continuous use in a way that suits a patient's everyday lifestyle.

OTHER MODALITIES FOR IMPROVING TISSUE OXYGENATION

Traditionally, vascular surgeons have performed arterial bypass surgery, or endovascular interventions such as angioplasty or stenting, to correct macrovascular issues. These procedures carry significant morbidity, and occasionally mortality, and many patients with chronic wounds have comorbidities and risk factors that do not make them ideal candidates for surgery (Slovut and Lipsitz, 2012; Sinha et al, 2014). In addition, these interventions primarily improve flow in larger arteries but cannot overcome the microvascular disease that is often the cause of poor tissue oxygenation in chronic wounds associated with diabetes and chronic venous hypertension (Forsythe et al, 2014; Wollina et al, 2006).

Pharmacological interventions aimed at improving blood supply and oxygenation may also be useful, such as the vasodilator iloprost, but these systemic treatments are associated with

potential side effects and may require short-term hospitalisation (Abdulhannan et al, 2012). Other therapies deliver topical nitric oxide (NO) to cause vasodilation (Del Rosso and Kircik, 2017), and while this works well when the vessels are healthy, when the vessels are heavily diseased or absent it is not possible to physically dilate the vasculature.

As oxygen is delivered to tissues via haemoglobin, topical haemoglobin therapy is another mode of wound treatment that has been under investigation in recent years (Chadwick et al, 2015). Topical haemoglobin is applied to the wound bed where it binds oxygen from the atmosphere and releases it to wound tissues (Dissemond et al, 2015). However, wet or impermeable dressings covering a wound may act as a barrier to atmospheric oxygen diffusing to the topical haemoglobin.

Oxygen and wound healing

THE ROLE OF OXYGEN IN HEALING

Oxygen is critical to many of the processes required in wound healing, including:

- Production of energy to fuel cell function and biochemical reactions
- Angiogenesis
- Collagen synthesis and cross-linking
- Epithelialisation
- Resistance to infection (Castilla et al, 2012; Eisenbud, 2012).

The presence of a wound increases the body's need for oxygen: by 20% for a patient with a clean wound and 50% for a patient with an infected wound (Demling, 2009). For healing, local cellular metabolic needs in the wound increase several-fold during the healing process; low wound oxygen levels significantly restrict energy production and therefore limit wound healing (Demling, 2009).

A recent systematic review compared the ability of ankle-brachial pressure index (ABPI) and transcutaneous oxygen measurement (TcPO₂) to predict the healing of DFUs and the risk of amputation. It found that TcPO₂ was a better predictor of both outcomes, indicating that the amount of tissue oxygen is positively correlated with the likelihood of healing (Wang et al, 2016).

A study assessing treatment of non-healing venous leg ulcers (VLUs) of over two years' duration compared standard treatment to topical oxygen therapy utilising a static chamber (Tawfik and Sultan, 2013). The study assessed proportion of ulcers healed at 12 weeks, recurrence rates, reduction in ulcer size, and time to full healing. Sixty-seven patients were managed using topical oxygen and 65 patients were managed with conventional compression dressings for 12 weeks or until full healing. Mean reduction in wound area at 12 weeks was 96% in patients managed with topical oxygen and 61% in patients managed with conventional compression dressings. At 12 weeks, 76% of the topical oxygen-managed ulcers had completely healed, compared to 46% of the control group ($p < 0.0001$). Median time to full healing was 57 days in patients managed with topical oxygen and 107 days in the control group ($p < 0.0001$).

After 36 months' follow-up, 14 of the 30 (47%) healed wounds in the control group showed recurrence compared to 3 of the 51 (6%) oxygen-healed ulcers. Topical oxygen therapy was found to be effective and valuable in managing non-healing VLUs, reducing the time required for healing and radically decreasing recurrence rates. Collagen formed in hypoxic environments is known to be only about one third as strong as normal (Kominsky et al, 2010), and it may be that topical oxygen therapy improves the quality of wound healing as well the rate of wound closure.

While this study demonstrated the efficacy of topical oxygen therapy in practice, treatment was delivered using a localised hyperbaric chamber. This meant that the patients were limited in mobility and everyday life while receiving treatment.

CAUSES OF WOUND HYPOXIA

Wound hypoxia – a relative lack of oxygen in the wound tissues due to the amount of oxygen delivered being below the amount needed by the wound – is often multifactorial. Wound hypoxia may be due to reduced delivery of oxygen to tissues (due to systemic or local disease) and/or due to increased oxygen demand by wound tissues. Patients with poorly healing wounds may have several factors that contribute to wound tissue hypoxia. Causes of reduced delivery of oxygen to wound tissues include:

- **Macrovascular disease** – e.g. reduced arterial blood flow due to peripheral arterial disease or reduced diffusion of oxygen through tissues due to oedema caused by venous disease (Sen et al, 2009; Schreml et al, 2010)

- **Microvascular disease** – e.g. capillary wall thickening and/or arteriovenous shunting with diabetes, fibrin deposition in chronic venous hypertension, vasculitis (Howard et al, 2013)
- **Chronic wound inflammation** – the presence of wound biofilm sets up a chronic inflammatory state where oxygen consumption by immune cells such as neutrophils and macrophages contributes to low wound oxygen levels (James et al, 2016)
- **Systemic disease** – e.g. reduced arterial oxygen levels due to respiratory disease, heart disease or anaemia (Sen, 2009; Schreml et al, 2010).

Other factors that may contribute to tissue hypoxia include pulmonary fibrosis or pneumonia, sympathetic dysregulation, hypothermia, haemodynamic instability, the need for vasopressors, cardiovascular disease, Raynaud's disease and high altitude (Park et al, 2014).

With an increasingly large cohort of ageing patients within the general population, it is important to assess for underlying factors that can contribute to tissue hypoxia, while keeping in mind that chronic wounds are typically in a hypoxic state (Harding, 2016).

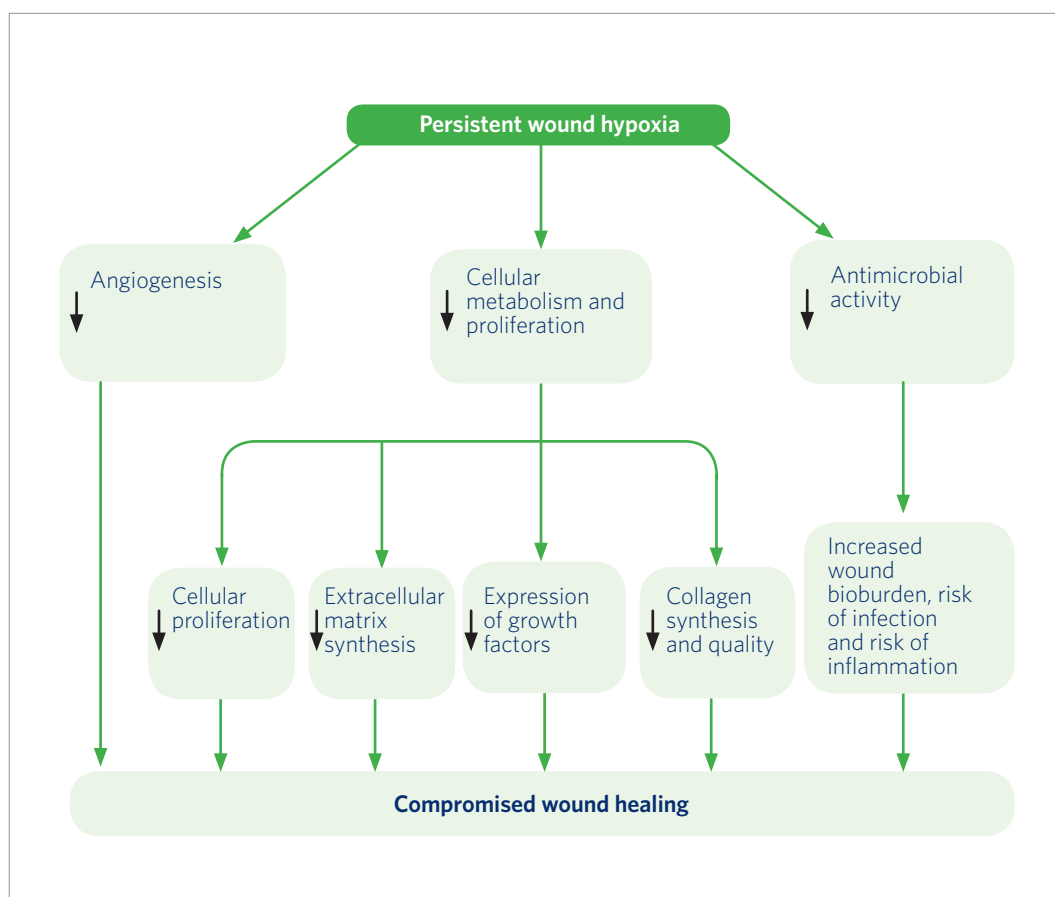
UNDERSTANDING THE IMPACT OF LOW OXYGEN ON TISSUE REPAIR

Wound tissue hypoxia is an important initiator of wound healing (Schreml et al, 2010). However, once healing has been initiated, adequate levels of oxygen are very important for healing to progress and for full re-epithelialisation (Yip, 2015). Persistent wound hypoxia, e.g. as a result of vascular disease, can have a multitude of deleterious effects that delay healing and promote wound chronicity (Table 1 and Figure 1; Guo and DiPietro, 2010).

TABLE 1: Effects of persistent hypoxia on wound healing (Gottrup, 2004; Gibson et al, 2009; Sen, 2009; Castilla et al, 2012; Eisenbud, 2012; Howard et al, 2013; Zhao et al, 2016)

Effect of persistent hypoxia	Impact on wound healing
Reduced oxygen availability for cell metabolism	<ul style="list-style-type: none"> ■ Impairs the ability of cells to generate energy and so may reduce synthesis of proteins, DNA, RNA and cell components
Reduced fibroblast proliferation	<ul style="list-style-type: none"> ■ Fewer fibroblasts results in lower collagen production ■ Hypoxia may also impair differentiation of fibroblasts into myofibroblasts, which are important for wound contraction
Reduced synthesis of collagen	<ul style="list-style-type: none"> ■ Synthesis, cross-linking, tensile strength and maturation of collagen are impaired when oxygen levels are reduced, resulting in delayed healing and reduced scar strength
Reduced antimicrobial activity	<ul style="list-style-type: none"> ■ Low oxygen levels impair the ability of immune cells to generate the reactive oxygen species used to prevent bacterial colonisation of wound infection ■ Bacterial growth may use oxygen and worsen hypoxia
Reduced angiogenesis	<ul style="list-style-type: none"> ■ Delivery of nutrients and oxygen to wound tissues is limited
Perpetuation of inflammation	<ul style="list-style-type: none"> ■ Excessive protease production may occur that delays healing by degrading extracellular matrix and growth factors

Figure 1: Effects of persistent wound hypoxia on wound healing (Gotttrup, 2004; Castilla et al, 2012; Howard et al, 2013; Zhao et al, 2016)



Research into oxygen levels in wound healing has found:

- The oxygen level 3–4mm below the surface of normal skin is about 45–65mmHg (Howard et al, 2013)
- Chronic wound tissues have an oxygen level of 5–20mmHg (Schreml et al, 2010), but in central devascularised regions of a wound oxygen levels can be as low as 0–5mmHg (Howard et al, 2013)
- Wound cells convert to anaerobic metabolism at oxygen levels below 20mmHg, slowing the processes of wound healing (Howard et al, 2013).

However, research has also found that many aspects of wound healing can take place at their highest rates at much higher oxygen levels than are usually seen in wounds or even in normal skin:

- Fibroblast proliferation and protein production is maximal at oxygen levels of 160mmHg (Howard et al, 2013)
- The activity of a key enzyme for collagen production, prolyl hydroxylase, is maximal at oxygen levels of around 250mmHg (Hutton et al, 1967).

These findings suggest that supplying wounds with additional oxygen that raises tissue oxygen levels above usual physiological levels has the potential to boost healing (Howard et al, 2013).

CELL METABOLISM AND ENERGY PRODUCTION

Oxygen is required by cells to facilitate intracellular processes, as well as cell survival. Nearly all cellular processes use energy in the form of adenosine triphosphate (ATP). In hypoxic tissue, one molecule of glucose can be processed to generate only two molecules of ATP, but when oxygen is plentiful, one glucose molecule produces 36 molecules of ATP (Lordish et al, 2000). Several enzymes required for healing are oxygen-dependent. The increased energy demands of healing tissue lead to a hypermetabolic state, in turn increasing the oxygen demand of the healing tissue (Ichioka et al, 2008).

Oxygen is also required for the respiratory burst, which releases the reactive oxygen species required to produce the cellular signalling messengers required for wound healing (Sen, 2003).

If oxygen levels are too low (<20mmHg), cells convert to anaerobic metabolism and go into 'survival mode', which impairs wound healing activities, such as cell division, and therefore re-epithelialisation, and collagen production (LaVan and Hunt, 1990; Hess et al, 2003; Hunt, 1990).

When low oxygen levels continue, prolonged exposure to this hypoxic environment can eventually cause cell death and tissue necrosis, due to the inability of the cells to repair the spontaneous decay of cell components (DNA, RNA, proteins) and inability to maintain calcium pumps (Milton and Prentice, 2007; Stys et al, 1990).

CELL PROLIFERATION AND RE-EPITHELIALISATION

Epithelial cells close the wound and form a barrier between the wound and the environment. While hypoxia can slow down the re-epithelialisation process, the addition of pure oxygen over a diabetic wound has been shown to increase the rate of wound closure by as much as 69%, indicating more rapid re-epithelialisation (Asmis et al, 2010).

It has been shown that fibroblast proliferation and protein production are optimal at an oxygen level of 160mmHg. This oxygen level is several times higher than that found in healthy tissues, indicating that supplemental oxygen may increase the rate of wound repair (Pandit and Faldman, 1994).

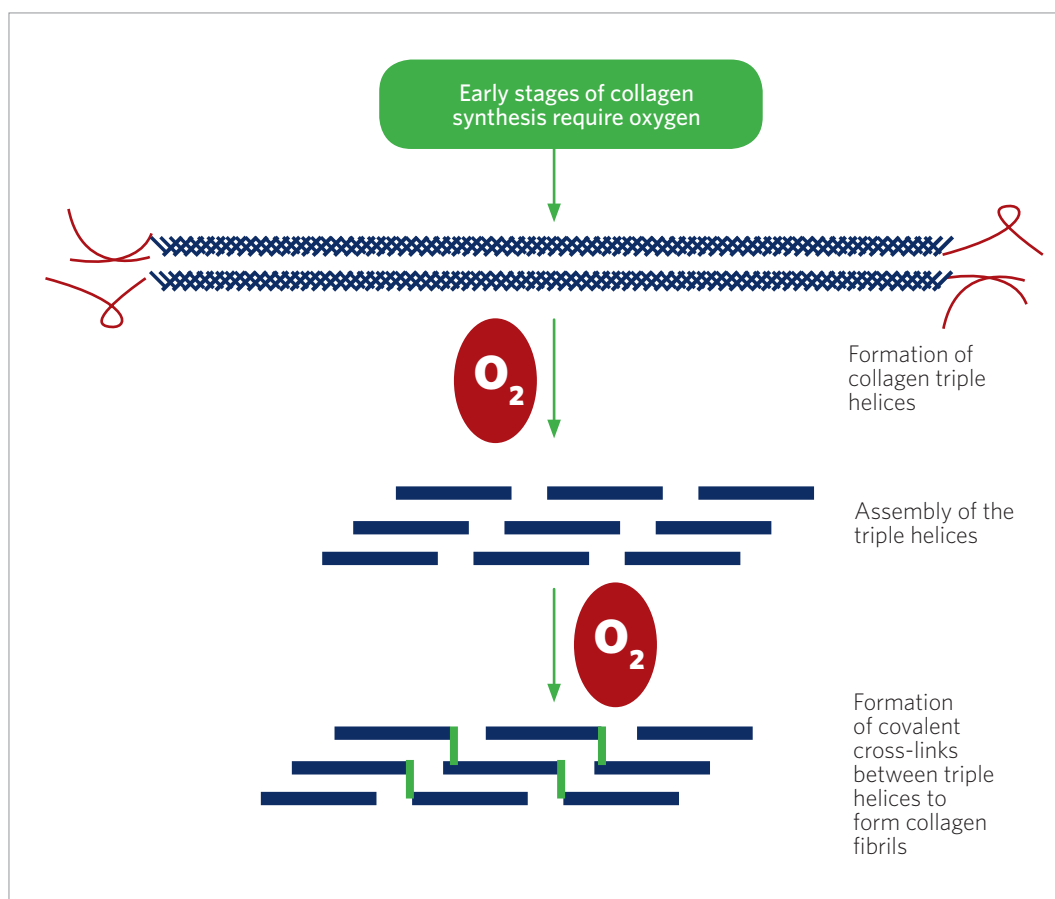
Endothelial progenitor cells (EPCs) are essential to vasculogenesis in wound healing. Their numbers and distribution have been found to be reduced in diabetic patients. However, elevated oxygen levels have been found to reverse these effects (Gallagher et al, 2007).

COLLAGEN SYNTHESIS

Collagen acts as the 'structural scaffold' of skin and is also the skin's primary component, accounting for 70-80% of its dry weight. Collagen is bundled into fibres (like the strands in a rope), which are interwoven like fabric and can be stretched in multiple directions (Hunt, 1990).

Figure 2 illustrates the extent to which collagen synthesis is oxygen-dependent, requiring multiple enzymes that all require oxygen to function (Gordillo and Sen, 2003). Higher oxygen concentrations have been found to increase both the amount of collagen production and its tensile strength (Stephens and Hunt, 1971). Maximal collagen production occurs at oxygen

Figure 2: Oxygen and collagen synthesis (adapted from Sen 2009; Shoulders & Raines, 2009)



levels of around 250mmHg, levels that exceed those present in normal wounds (often around 30–40mmHg; Hutton et al, 1967).

Collagen formed in hypoxic environments has been found to be only 30% as strong as collagen formed in normal oxygen concentrations (Kominsky et al, 2010). This is likely to have a significant effect on the quality of healed skin and may go some way to explaining why chronic, hard-to-heal wounds have a relatively high recurrence rate.

ANTIBACTERIAL ACTIVITIES

Oxygen is essential during the neutrophil or macrophage respiratory burst to produce the powerful reactive oxygen species (ROS) that are important in microbe clearance. The respiratory burst depends on oxygen to function effectively (Wang et al, 2007). As a result, hypoxia is associated with an increased risk of wound infection (Eisenbud, 2012). This creates a vicious circle, as growth of bacteria in the wound may consume oxygen and further exacerbate hypoxia (Eisenbud, 2012).

Maximal ROS production is seen at oxygen levels of greater than 300mmHg (Allen et al, 1997). Such high levels can only be achieved through the use of supplemental oxygen. It is likely therefore that bacterial clearance can be accelerated through the use of topical oxygen, and the effect may occur even if a wound is not already hypoxic.

In terms of its impact on bacterial burden, the efficacy of high concentrations of inspired supplemental oxygen on hypoxic and easily infected chronic wounds has been shown to be similar to antibiotic administration (Knighton et al, 1984). Such a finding is particularly interesting given the increasing issue of antibiotic resistance.

ANGIOGENESIS AND REVASCULARISATION

Angiogenesis is the formation of new blood vessels, which is essential to the growth and health of regenerating tissue. The rate and quality of blood vessel growth has been found to be directly affected by oxygen levels, with supplemental oxygen accelerating blood vessel growth (Knighton et al, 1981).

Angiogenesis is connected to the formation of good-quality collagen. The rate of angiogenesis is directly proportional to oxygen levels in injured tissues and rates of collagen deposition also increase proportionally with oxygen levels (Hopf et al, 2005).

See Box 1 for a summary of the effects of topical oxygen therapy on wound healing

BOX 1: Summary of the effects of topical oxygen therapy on wound healing

Topical oxygen therapy:

- Enables fuel production for cell proliferation and stimulates the healing cascade in stalled or chronic wounds
- Improves angiogenesis and revascularisation
- Improves bactericidal activity and microbe clearance, which results in lower rates of infection and biofilm
- Improves strength and quality of collagen, resulting in good-quality tissue formation as healing progresses, which may reduce future skin breakdown and reduce recurrence rates

Understanding NATROX oxygen wound therapy

NATROX is a class IIb medical device licensed under Medical Device Directive 93/42/EEC, which enables clinicians to prescribe pure humidified oxygen applied directly to a wound to assist wound healing in chronic or non-healing wounds (Figure 3).

Figure 3: The NATROX device



The NATROX Oxygen Wound Therapy System comprises an oxygen generator (OG) and the oxygen delivery system (ODS). The device contains a small rechargeable battery that operates an oxygen concentrator, which generates 98% oxygen through the electrolysis of water that is naturally present in the atmosphere.

The energy produced by the battery creates a positive charge on one face of the membrane inside the OG, and a negative charge on the other face. This charge then splits the hydrogen and oxygen that forms water, pulling the positive hydrogen ions one way and the negative oxygen ions the other. The hydrogen ions then recombine with oxygen molecules from the air to form more water, which then splits again across the membrane. The oxygen ions combine in pairs to form oxygen molecules which accumulate and then start to 'flow' down the tubing to the ODS.

The oxygen that is generated is delivered at a rate of around 15ml/hr through a fine, soft tube to a specially designed 'oxygen distribution system' (ODS) that is placed over the wound. The oxygen then diffuses evenly and continuously across the wound surface while the device is in operation.

The lightweight and compact size of the device means it is portable and can be used at all times, as it is suitable for wear under clothing during the day and can be positioned comfortably for use at night. This mode of delivery compared to other topical oxygen treatments means that oxygen can be used in a more practical and patient-friendly – and therefore better tolerated – way (Table 2). In a pilot study conducted in Cambridge and London, DFU patients rated the acceptability of using the device night and day, giving it an overall score of 9.9/10 (Data on file, Inotec AMD Ltd).


TABLE 2: Wound oxygen therapies compared (Tawfick and Sultan, 2012; Eggleton et al, 2015; Data on file, Inotec AMD Ltd)			
	Hyperbaric oxygen therapy	Local perfusion via extremity chambers	Topical oxygen therapy: NATROX
Estimated local oxygen levels at wound during treatment* (mmHg)*	1800	800	650
Daily oxygen exposure (hours)	1.5	5	23
% of the week receiving therapy**	4	21	96
*Calculated on the basis that 100% oxygen at 1 atmosphere = 760mmHg. **Calculated on the basis of treatment occurring for 5 days/week for hyperbaric oxygen therapy and 7 days/week for the other oxygen treatment systems.			

Although hyperbaric oxygen can deliver very high levels of oxygen, it has struggled to gain widespread acceptance in the UK, at least partly because of the limited evidence for its efficacy (Margolis et al, 2013). A major reason for its lack of effect may be that the wounds are only subjected to increased levels of oxygen for very short periods of the week, leaving the chronic wound hypoxic for the majority of the time. In addition, hyperbaric oxygen therapy is expensive and requires considerable time commitment from the patient (Johnston et al, 2016).

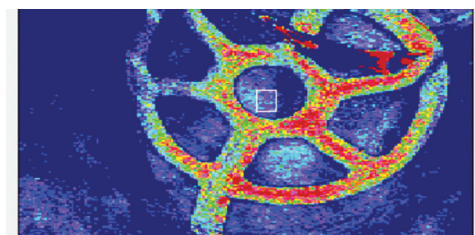
The oxygen delivered by NATROX can penetrate healthy skin and this is demonstrated in Figure 4. In this figure, lower levels of oxygenated haemoglobin are blue and higher levels are seen as red. The change in colour in Figure 4b (when NATROX has been switched on) shows that the oxygen has penetrated far enough into the tissues to enter the capillary bed and bind to de-oxygenated haemoglobin.

The oxygen diffuses into wound tissues because of the concentration gradient (higher on the surface of the wound and lower in the wound tissues); it is not forced into the tissues under pressure. In larger wounds, e.g. larger VLU's, the oxygen will diffuse over the whole of the wound. However, it may take longer to reach optimum oxygen concentration levels and therefore continuous treatment remains important.

Figure 4: Oxygenated haemoglobin levels in healthy skin with NATROX switched off (a) and on (b) - see text for explanation (Data on file, Inotec AMD Ltd)



A



B

See Table 3 for a summary of clinical evidence specifically for topical oxygen therapy using NATROX

TABLE 3: Summary of clinical evidence for NATROX

Author	Title	Type of study	Key points
Yu et al (2016)	Topical oxygen therapy results in complete wound healing in diabetic foot ulcers	RCT of NATROX (n=10) versus non-placebo control (n=10) in patients with a DFU	<ul style="list-style-type: none"> ■ Mean duration of DFU prior to study start was 76 weeks ■ Standard care for both groups included offloading ■ After 8 weeks of treatment: 90% of wounds treated with NATROX healed versus 20% in the control group
Kaufman (2016)	A new approach in oxygen wound therapy: an overview of NATROX™ experience in Israel	Observational study of NATROX in wounds of varied aetiology: VLU, peripheral vascular disease, DFUs, traumatic wounds, pressure ulcers and burns (n=75)	<ul style="list-style-type: none"> ■ For all wounds: mean duration of NATROX treatment was 36 days; 56% reduction in wound area during treatment ($p<0.001$) ■ For VLUs: mean duration of treatment was 42 days; 80% reduction ($p<0.0001$) ■ For DFUs and peripheral vascular disease wounds: mean duration of treatment was 28 days; 18% reduction ($p<0.05$) ■ NATROX therapy was extremely well tolerated by patients
Hayes et al (2015)	Topical oxygen therapy helps healing of diabetic foot ulcers	Case series of DFUs treated with NATROX (n=10)	<ul style="list-style-type: none"> ■ Median duration of DFUs was 25 weeks (mean 43 weeks) ■ After 8 weeks of treatment with NATROX, median DFU size had decreased by 53% and 7/10 ulcers were on a healing trajectory
Curran et al (2016)	27 years of non-healing wounds – 5 patients' lives transformed by topical oxygen therapy	Case series of patients with critical limb ischaemia and chronic ulcers (n=5)	<ul style="list-style-type: none"> ■ Total duration of the five chronic ulcers was >25 years ■ All ulcers healed during treatment with NATROX and patients reported improved quality of life ■ Average treatment duration to achieve full closure was 22.4 weeks ■ Patients expressed high levels of satisfaction with the device ■ Total cost of treatment with NATROX for the five patients was £9,856 compared with the total cost of previous standard dressing care of £120,144
TODFU-2 Collaborators (2016)	Topical Oxygen in Diabetic Foot Ulcers-2: 18 centre, UK-wide study	Ongoing observational study in patients with DFUs (n=40)	<ul style="list-style-type: none"> ■ DFUs had a mean duration of 19 months ■ A reduction in median wound area of 50% took 6.3 weeks of treatment with NATROX ■ Over 24 weeks, median wound area reduced from 1.75cm² to 0.11cm² ($p<0.01$)
Mani (2010)	Topical oxygen therapy for chronic wounds	Observational study in patients with VLUs (n=10)	<ul style="list-style-type: none"> ■ Wound area reduced by a mean of 58.9% over the 6 week study period ■ No adverse events were noted ■ Pain scores decreased in all patients

Indications for use of NATROX in diabetic foot ulcers and beyond

The Expert Working Group agreed that the science behind topical oxygen therapy is persuasive and that clinical evidence and experience to date show that NATROX has a role in managing DFUs, with early studies showing an improvement in wound healing times for this aetiology (Yu et al, 2016).

A potential treatment pathway for NATROX (Figure 5) has been developed by the Expert Working Group. Clinical experience of the use of NATROX in DFUs has been used to include chronic wounds of all types and other wounds that are at risk of reduced healing. **NATROX may be considered in patients who are likely to suffer from local or systemic oxygenation problems and whose wounds are deemed unlikely or slow to heal.** The pathway takes particular consideration of:

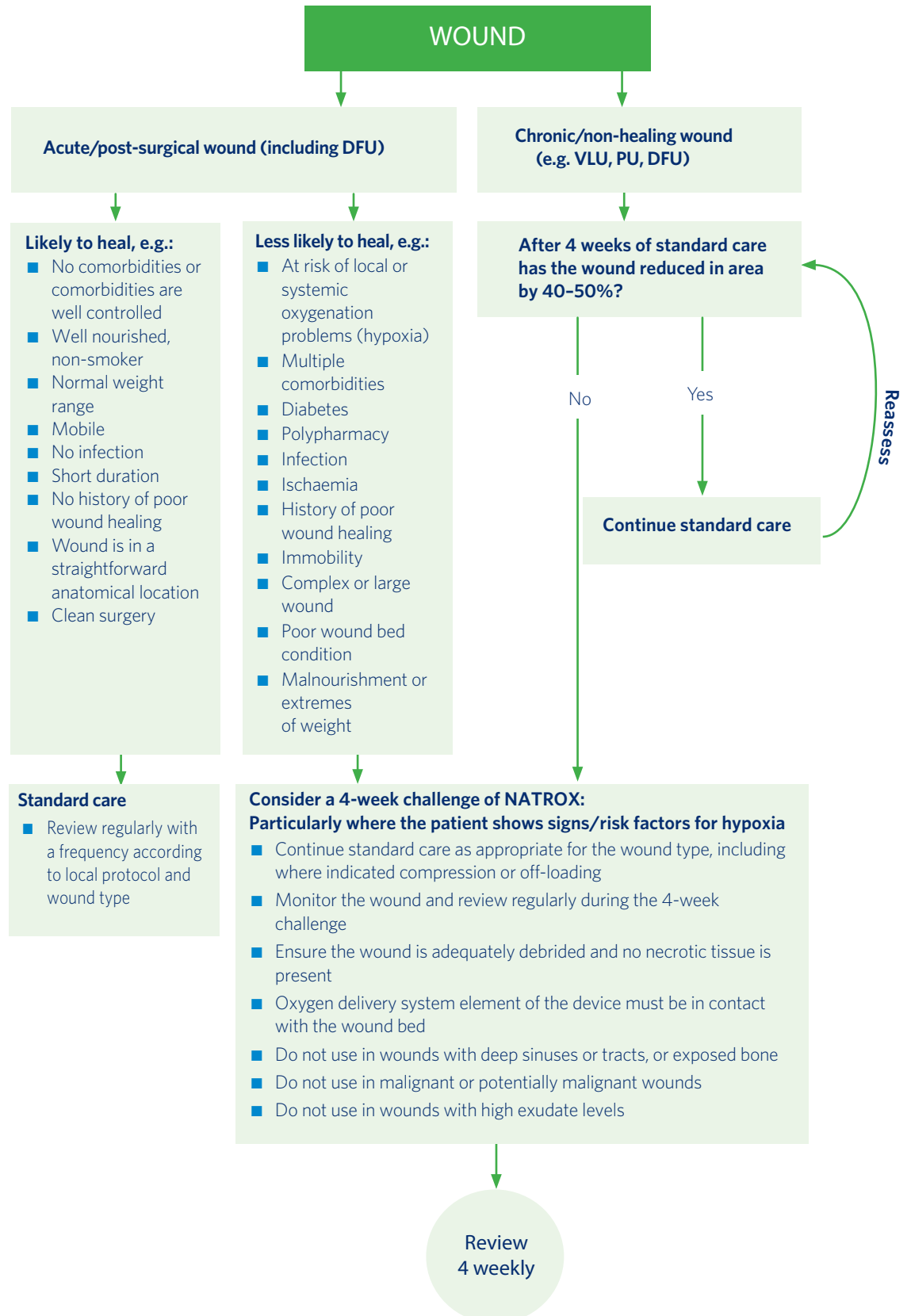
- **Chronicity** – NATROX is indicated for chronic wounds and non-healing DFUs. The Expert Working Group defined these wounds as failing to reduce in area by at least 40–50% with 4 weeks of standard treatment (WUWHS, 2016)
- **Infection level** – NATROX should not be used in cases of severe or systemic wound infection, but may be used on locally infected wounds
- **Depth** – NATROX can be used on deep wounds, but is contraindicated in the presence of exposed bone or in wounds with deep sinuses or tracts
- **Exudate levels** – NATROX may not be suitable for wounds with very high levels of exudate
- **Wound bed quality** – the oxygen delivery system element of the NATROX device must be in direct contact with the wound bed and should not be used in the presence of necrotic tissue.

TcPO₂ measurement is a relatively straightforward clinical test and has been shown to have a high diagnostic index in predicting the healing of DFUs (Wang et al, 2016). As a result and with further research, TcPO₂ measurement may become incorporated into patient pathways for NATROX as a way of identifying patients who may benefit from topical oxygen therapy.

ANGIOPLASTY AND NATROX

The Expert Working Group discussed the potential for using NATROX prior to angioplasty in the hope that wound oxygenation may improve sufficiently to avoid angioplasty altogether. At present, vascular surgeons and interventional radiologists undertake interventions to improve blood flow and tissue oxygenation to the lower limbs to heal wounds. These interventions are associated with morbidity, and occasionally mortality, in addition to carrying a significant cost. The group considered that NATROX may be a useful adjunctive intervention to improve the condition of the wounds pre- and post-angioplasty.

Figure 5: Potential role of NATROX in wound care



REASSESSMENT PROTOCOL: THE 4-WEEK CHALLENGE

In all wounds, after 4 weeks of treatment with NATROX, the patient and the wound should be reassessed and treatment options considered. At the 4-week point, the treatment should be assessed against the aims that were defined at the start of treatment.

Clinical experience has found that it is not unusual for the wounds to increase in size over the first couple of weeks as the non-viable tissue is cleared by the newly active macrophages and neutrophils. As a result, although the improvement may not seem significant at 4 weeks, unless the wound has deteriorated, continuation of treatment should be considered as there may be long-term benefits due to the production of better quality collagen.

If the treatment is successfully meeting the defined aims – e.g. the wound is improving, or treatment is helping to manage pain or other symptoms as defined – consideration may be given to extending treatment for another 4 weeks before further reassessment.

With chronic wounds that are prone to recurrence, it is helpful to define healing using the Leg Club Model, which does not classify a wound as officially 'healed' until 2 weeks after wound closure, due to the fragility of the healed tissue (Lindsay, 2004). The Leg Club Model relates to VLUs, but the concept may also be helpful in other wound types. The continued use of topical oxygen therapy may aid fibroblast activity and collagen maturation in the tissue below the newly formed epithelium, and so possibly reduce the risk of wound recurrence.

Case studies

The cases below illustrate good results in post-surgical diabetic foot wounds and are taken from a randomised controlled trial being conducted in Cardiff that is comparing the use of NATROX with standard care.

The trial is ongoing: to date, 83% of participants have achieved complete re-epithelialisation and none has re-ulcerated at the endpoint of 24 weeks. Only 14% developed clinical features of wound infection. Both patients and clinicians reported that the NATROX device was easy to operate.

CASE 1

This male patient has type 1 diabetes, cardiac failure, peripheral arterial disease and a history of angioplasty. The patient had a DFU following amputation. Topical oxygen therapy commenced 4 weeks post-operatively (Figure 6). Treatment continued for 6 weeks before the patient was withdrawn due to a significant adverse event to the contralateral limb. Improvement to the NATROX-treated wound was seen over the course of treatment (Figure 7).

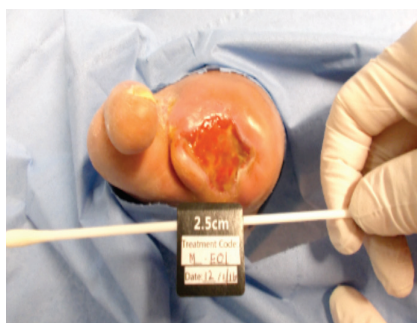


Figure 6: Case 1 at start of NATROX treatment

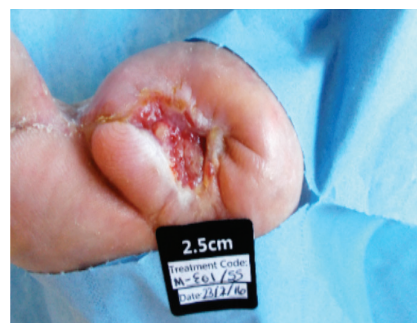

Figure 7: Case 1 at end of NATROX treatment

CASE 2

This female patient has type 1 diabetes and a previous right below-knee amputation. She also has peripheral arterial disease and a history of angioplasty. Following multiple amputation of toes and an indolent plantar DFU on her left foot of 6 months' duration, NATROX was commenced (Figure 8) and continued for 16 weeks to healing (Figure 9).

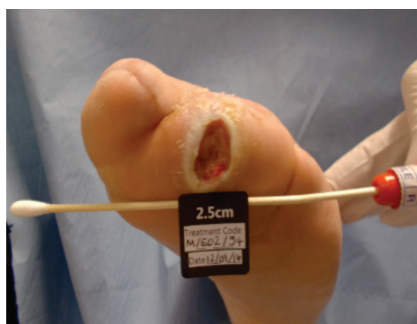


Figure 8: Case 2 at start of NATROX treatment

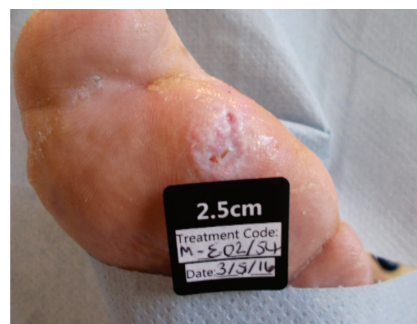

Figure 9: Case 2 at end of NATROX treatment

CASE 3

This female patient has type 2 diabetes and peripheral neuropathy. She has a history of recurrent DFU and complications with osteomyelitis, and uses bespoke footwear. NATROX was commenced 12 weeks post-trauma on the DFU on the patient's right foot (Figure 10) and continued for 4 weeks to healing (Figure 11).

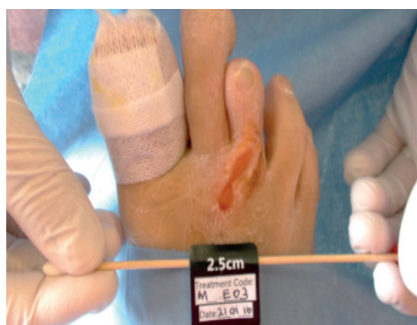

Figure 10: Case 3 at start of NATROX treatment

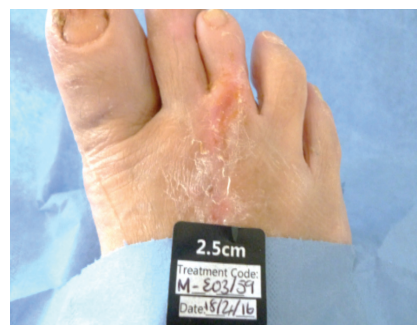

Figure 11: Case 3 at end of NATROX treatment

Indications for use in other wounds

Evidence gained from using NATROX to treat DFUs can be extrapolated and applied to a wider variety of wounds, providing benefits to both patients and practitioners. Considerable experience has already been gained with venous and mixed aetiology leg ulcers. Trials are underway to gain experience of benefits in other wound types including surgical wound dehiscence and pressure ulcers.

LEG ULCERS

NATROX has shown good results in the management of VLUs (Table 3, page 11). The device can be used in all patients with VLUs, including in conjunction with compression therapy and in the presence of oedema or atrophie blanche. It may also be used in ischaemic or mixed aetiology leg ulcers.

A recent meta-analysis found the prevalence of biofilm in wounds to be 78.2% (Malone et al, 2017). As oxygen therapy boosts antibacterial activity, it may be particularly useful in treating infection and suspected biofilm in chronic leg ulcers. Biofilm is common in chronic VLUs and can be a precursor to infection and further delayed healing. Therefore, prevention and disruption of biofilm forms a key part of treatment in such chronic wounds (Phillips et al, 2010). Risk factors for biofilm and consequent delayed healing in VLUs include tissue ischaemia or necrosis (although these are rare in VLUs), poor nutrition and comorbidities that impair immune function. Patients with VLUs and such risk factors are potentially good candidates for NATROX.

Patients with VLUs often present with repeated cycles of ulceration, healing, and recurrence (Wounds UK, 2016). Chronic VLUs can take weeks or months to heal, and recurrence is a significant issue: 12-month recurrence rates are estimated as between 18% and 28% (Ashby et al, 2014). Therefore skin condition and quality of healing tissue in VLU patients is a significant issue. The improvement in good-quality collagen formation observed in topical oxygen therapy may also help to support fragile skin that is prone to recurrent ulcers.

Indications for use in leg ulcers include in patients with uninfected or locally infected non-venous leg ulcers and low ABPI. It is recommended that clinicians consider NATROX and use the 4-week challenge approach (page 14): if there is no improvement in 4 weeks, treatment should be discontinued; and if there is progress, continuation of NATROX should be considered for a defined further treatment period.

Additionally, in patients with leg ulcers and a normal ABPI, where no improvement has been seen in 4 weeks or improvement is slow – i.e. a reduction in wound area of less than 40% in the 4-week period – NATROX should be considered as a new treatment option. In all cases, NATROX should be used along with standard care including debridement, compression and moist wound healing.

POST-OPERATIVE AND DEHISCED ABDOMINAL WOUNDS

Most surgical procedures or interventions result in a break in the skin's natural protective barrier, increasing the risk of bacterial contamination or other complications (Milne et al, 2012). Post-operative wound complications carry a significant morbidity and mortality, and incurrance of additional costs. However, most post-operative complications are preventable. Surgical site infection is the most common post-operative complication, followed by post-operative blistering and wound dehiscence (Milne et al, 2012).

NATROX can be used in cases of dehisced abdominal wounds and may be particularly useful in instances where extensive scarring may be likely. In post-operative wounds, the potential for improved collagen could be beneficial to the healing process and in limiting scarring and

optimising perfusion, e.g. in burns, high-risk orthopaedic incisions (particularly knee and hip replacements), amputation wounds and bariatric surgery wounds. It may also be useful in preventing infection.

GENERAL CONSIDERATIONS

When considering NATROX for any wound type, the Expert Working Group has suggested that it may be useful to take into consideration potential risk factors for delayed healing, including those that may specifically cause tissue hypoxia, such as respiratory (or cardiac) issues or vascular disease (Box 2). Contraindications to NATROX are listed in Box 3.

BOX 2: Factors indicating early consideration of topical oxygen therapy

- Diabetes
- Respiratory, cardiac or vascular disease
- Long-term use of certain medications – e.g. steroids
- Increased age
- Smoking
- Bariatric patients
- History of recurrent ulcers/skin breakdown/wounding
- Increased risk of scarring

BOX 3: Contraindications to NATROX

The NATROX system is contraindicated for the following:

- Wounds being treated with topical ointments or creams
- Inadequately debrided wounds
- Wounds with deep sinuses or tracts, or with exposed bone present
- Patients unable to tolerate occlusive/adhesive dressings
- Potentially malignant wounds or ulcers

CONCORDANCE WITH TREATMENT

It was agreed that patients and clinicians found NATROX easy to use and not at all cumbersome. Generally, members of the Expert Working Group with experience of NATROX reported very positive feedback, especially in view of impressive improvement in healing, and quality of life factors such as pain, odour and exudate management (see box 'What to expect from treatment', page 18).

NATROX: Tips for use

Topical oxygen therapy will generally be used as an adjunct therapy in conjunction with other treatments and dressings, and it is important that this is managed correctly in order to optimise treatment.

WOUND BED PREPARATION

For NATROX therapy to work efficiently, the oxygen delivery system element of the device should be in direct contact with the wound and all physical barriers to its efficacy should be removed. Proper debridement and wound bed preparation are key to successful use of topical oxygen therapy.

DRESSING SELECTION

It is important to select an appropriate secondary dressing to use in conjunction with the device. The dressing is needed to protect the wound, absorb exudate, promote comfort and secure the system in position.

An occlusive, non-adherent dressing should be used, although larger or wet wounds may require more absorbent dressings. Gel dressings should be avoided as they may interfere with oxygen delivery.

NATROX Treatment Tips: Dos and Don'ts

- DON'T** use in conjunction with creams or similar topical treatments, as these can act as a barrier to oxygen absorption
- DO** consider placement of tubing to reduce the risk of potential pressure damage – ensure the tube is tracking away from the patient and the surrounding skin is protected
- DO** make sure the oxygen distribution element of the device is in direct contact with the wound bed and appropriate debridement has removed all barriers
- DO** consider appropriate dressing choice
- DO** consider continuing treatment after wound closure for a short duration

What to expect from NATROX treatment based on clinical experience

- As a by-product of the treatment, wounds may become larger in size before healing and exudate levels may increase. Approximately 50–60% of wounds treated with topical oxygen were found to increase in size initially, before going on to reduce and heal
- It should be noted that fluid/exudate levels usually increase for the first 2 weeks after commencing topical oxygen therapy, so increased dressing change frequency is recommended to prevent maceration – e.g. if dressing change was previously twice per week, increase to three times per week until exudate levels reduce. The consumable part of NATROX, the Oxygen Delivery System (ODS), should be changed at every dressing change
- Initially some change in appearance of granulation tissue has been observed – the tissue may change/darken in colour and resemble hypergranulation tissue, before going on to develop into good-quality healing tissue
- Many groups have anecdotally reported reduction in pain levels when using topical oxygen therapy, although no formal published data is yet available. In VLU's, this may be helpful in potentially getting patients into compression therapy

Summary

The vital role of oxygen in wound healing has long been acknowledged, and innovations in the method of delivery mark a potential new development in the application of topical oxygen therapy.

Early evidence and case studies indicate promising use of NATROX as a topical oxygen delivery system. Its portable and lightweight format may help to promote patient acceptability and concordance.

The experience of using NATROX in diabetic foot ulcers may be extrapolated to a range of further wound types, as well as being developed to aid prevention in patients with a range of risk factors and reduce recurrence rates in patients with fragile skin.

Its positive effects on healing time, infection rates and quality of healing may have a range of benefits, including reduced clinician time and costs, as well as benefits to patient experience and quality of life.

Potential future developments

- Developing the role of NATROX in avoiding revascularisation and amputation
- Developing the role of NATROX in preventing chronicity in leg ulcers
- Developing the role of NATROX in boosting oxygenation to aid healing of high-risk surgical incisions
- Developing the role of NATROX in plastic surgery for improving graft take and healing of breast reconstruction wounds
- Developing the role of NATROX in managing pilonidal sinus wounds
- Using NATROX in conjunction with, or following, negative pressure wound therapy (NPWT) treatment

References

- Abdulhannan P, Russell DA, Homer-Vanniasinkam S (2012) Peripheral arterial disease: a literature review. *Br Med Bull* 104: 21-39
- Allen DB, Maguire JJ, Mahdavian M et al (1997) Wound hypoxia and acidosis limit neutrophil bacterial killing mechanisms. *Arch Surg* 132: 991-6
- Ashby RL, Gabe R, Ali S, Adderley U (2014) Clinical and cost-effectiveness of compression hosiery versus compression bandages in treatment of venous leg ulcers (Venous leg Ulcer Study IV, VenUS IV): A randomized controlled trial. *Lancet* 383(9920): 871-9
- Asmis R, Qiao M, Zhao Q (2010) Low-flow oxygenation of full-excisional skin wounds on diabetic mice improves wound healing by accelerating wound closure and reepithelialization. *Int Wound J* 7: 349-57
- Boerema I, Kroll J, Meijne NG et al (1956) High atmospheric pressure as an aid to cardiac surgery. *Arch Chir Neerl* 8: 193-211
- Brummelkamp WH, Hogendijk J, Boerema I (1961) Treatment of anaerobic infections (clostridial myositis) by drenching the tissues with oxygen under high atmospheric pressure. *Surgery* 49: 299-302
- Castilla DM, Liu Z-J, Velazquez OC (2012) Oxygen: implications for healing. *Adv Wound Care* 1(6): 225-30
- Chadwick P, McCordle J, Mohamud L (2015) Appropriate use of topical haemoglobin in chronic wound management: consensus recommendations. *Wounds UK, EWMA Special*, 30-5
- Curran G, Hayes PD (2016) 27 years of non-healing wounds - 5 patients' lives transformed by topical oxygen therapy. Poster presented at Wounds UK Conference, Harrogate
- Demling RH (2009) Nutrition, anabolism, and the wound healing process: An overview. *Eplasty* 9: e9
- Data on File. Inotech AMD Ltd.
- Del Rosso JQ, Kircik L (2017) Spotlight on the use of nitric oxide in dermatology: what is it? what does it do? can it become an important addition to the therapeutic armamentarium for skin disease? *J Drugs Dermatol* 16(1 suppl 1): s4-10.
- Dissemond J, Kröger K, Storck M, et al (2015) Topical oxygen wound therapies for chronic wounds: a review. *J Wound Care* 24(2): 53-63
- Eggleton P, Bishop AJ, Smerdon GR (2015) Safety and efficacy of hyperbaric oxygen therapy in chronic wound management: current evidence. *Chr Wound Care Manage Res* 2: 81-93
- Eisenbud DE (2012) Oxygen in wound healing. Nutrient, antibiotic, signaling molecule, and therapeutic agent. *Clin Plastic Surg* 39: 293-310
- Forsythe RO, Brownrigg J, Hinchliffe J (2014) Peripheral arterial disease and revascularization of the diabetic foot. *Diabetes, Obesity & Metab* 17: 435-44
- Gallagher KA, Liu ZJ, Xiao M et al (2007) Diabetic impairments in NO-mediated endothelial progenitor cell mobilization and homing are reversed by hyperoxia and SDF-1 alpha. *J Clin Invest* 117: 1249-59
- Gibson D, Cullen B, Legerstee R, et al (2009) MMPs Made Easy. *Wounds International* 1(1). Available at: www.woundsinternational.com
- Gordillo GM, Sen CK (2003) Revisiting the essential role of oxygen in wound healing. *Amer J Surg* 186: 259-63
- Gottrup F (2004) Oxygen in wound healing and infection. *World J Surg* 28: 312-5
- Guo S, DiPietro LA (2010) Factors affecting wound healing. *J Dent Res* 89(3): 219-29
- Harding K (2016) The essential role of oxygen in wound healing. Presentation. *Wounds UK*, Harrogate.
- Hess CL, Howard MA, Attinger CE (2003) A review of mechanical adjuncts in wound healing: hydrotherapy, ultrasound, negative pressure therapy, hyperbaric oxygen, and electrostimulation. *Ann Plast Surg* 51: 210-8
- Hopf HW, Gibson JJ, Angeles AP et al (2005) Hyperoxia and angiogenesis. *Wound Repair Regen* 13: 558-64
- Howard MA, Asmis R, Evans KK, Mustoe TA (2013) Oxygen and wound care: A review of current therapeutic modalities and future direction. *Wound Rep Regen* 21: 503-11
- Hayes P, Lee H, Curran G, Loftus I (2015) *Topical oxygen therapy helps healing of diabetic foot ulcers*. Poster presented at Canadian Association of Wound Care (CAWC) Conference, Toronto
- Hunt TK (1990) Basic principles of wound healing. *J Trauma* 30: S122-8
- Hutton J, Tappel A, Udenfried S (1967) Cofactor and substrate requirements of collagen proline hydroxylase. *Arch Biochem Biophys* 118: 231-40
- Ichioka S, Ando T, Shibata M et al (2008) Oxygen consumption of keloids and hypertrophic scars. *Ann Plast Surg* 60: 194-7
- James GA, Ge Zhao A, Usui M et al (2016) Microsensor and 16 transcriptomic signatures of oxygen depletion in biofilms associated with chronic wounds. *Wound Repair Regen* 24(2):373-83
- Johnston BR, Ha AY, Brea B, Liu PY (2016) The mechanism of hyperbaric oxygen therapy in the treatment of chronic wounds and diabetic foot ulcers. *R I Med J* 99(2): 26-9
- Kaufman H (2016) *A new approach in oxygen wound therapy: an overview of NATROX™ experience in Israel*. Abstract and presentation at World Union of Wound Healing Societies, Florence
- Knighton D, Halliday B, Hunt T (1984) Oxygen as an antibiotic: the effect of inspired oxygen on infection. *Arch Surg* 119: 199-204
- Knighton D, Silver I, Hunt T (1981) Regulation of wound healing and angiogenesis - effect of oxygen gradients and inspired oxygen concentrations. *Surgery* 90: 262-70
- Kominsky DJ, Campbell EL, Colgan SP (2010) Metabolic shifts in immunity and inflammation. *J Immunol* 184(8): 4062-8
- LaVan FB, Hunt TK (1990) Oxygen and wound healing. *Clin Plast Surg* 17: 463-72
- Lindsay E (2004) The Lindsay Leg Club Model: a model for evidence-based leg ulcer management. *Br J Community Nurs* Suppl:S15-20
- Lordish H, Berk A, Zipursky SL, et al (2000) Molecular cell biology. 4th edition. New York: Freeman.
- Malone M, Bjarnsholt T, McBain AJ, et al (2017) The prevalence of biofilms in chronic wounds: a systematic review and meta-

- analysis of published data. *J Wound Care* 28(1): 20-24
- Mani R (2010) Topical oxygen therapy for chronic wounds: a report on the potential of NATROX™ a new device for delivering enriched oxygen to chronic wounds. *J Wound Technol* 9: 28-30.
- Margolis DJ, Gupta J, Hoffstad O, et al (2013) Lack of effectiveness of hyperbaric oxygen therapy for the treatment of diabetic foot ulcer and the prevention of amputation. *Diabetes Care* 36(7): 1961-66
- Milne J, Vowden P, Fumarola S, Leaper D (2012) Postoperative incision management made easy. *Wounds UK* (8)12: s1-4
- Milton SL, Prentice HM (2007) Beyond anoxia: The physiology of metabolic down regulation and recovery in the anoxia-tolerant turtle. *Comparative Biochemistry and Physiology, Part A* 147: 277-90
- Pandit AS, Faldman DS (1994) Effect of oxygen treatment and dressing oxygen permeability on wound healing. *Wound Repair Regen* 2: 130-7
- Park N, Allen L, Nametka M, Driver VR (2014) Healing hypoxic wounds: fighting an uphill battle. *Lower Extrem Rev May*
- Phillips PL (2010) Biofilm Made Easy. *Wounds International* 1(3): s1-6
- Schreml S, Szeimies RM, Prantl L, et al (2010) Oxygen in acute and chronic wound healing. *Br J Dermatol* 163(2): 257-68
- Sen CK (2003) The general case for redox control of wound repair. *Wound Repair Regen* 11: 431-8
- Sen CK (2009) Wound healing essentials: let there be oxygen. *Wound Repair Regen* 17(1): 1-18
- Shoulders MD, Raines RT (2009) Collagen structure and stability. *Annu Rev Biochem* 78: 929-58
- Sinha S, Karthikesalingam A, Poloniecki JD, et al (2014) Inter-relationship of procedural mortality rates in vascular surgery in England. *Circulation: Cardiovascular Quality and Outcomes* 7: 131-41
- Slovut DP, Lipsitz EC (2012) Surgical technique and peripheral arterial disease. *Circulation* 126: 1127-38
- Smith G, Sharp GR (1962) Treatment of coal gas poisoning with oxygen at two atmospheres pressure. *Lancet* 1: 816-19
- Stephens F, Hunt T (1971) Effect of changes in inspired oxygen and carbon dioxide tensions on wound tensile strength. *Ann Surg* 173: 515
- Stys PK, Ransom BR, Waxman SG, Davis PK (1990) Role of extracellular calcium in anoxic injury of mammalian central white matter. *Proc Natl Acad Sci* 87:4212-6
- Tawfick WA, Sultan S (2009) Does topical wound oxygen (TWO2) offer an improved outcome over conventional compression dressings (CCD) in the management of refractory venous ulcers (RVU)? A parallel observational comparative study *Eur J Endovasc Surg* 38(1): 125-32
- Tawfick WA, Sultan S (2013) Technical and clinical outcome of topical wound oxygen in comparison to conventional compression dressings in the management of refractory non-healing venous ulcers. *Vascular and Endovascular Surgery* 47(1): 30-7
- TODFU-2 Collaborators (2016) *Topical Oxygen in Diabetic Foot Ulcers-2: 18 centre, UK-wide study*. Abstract and poster presentation at UK Vascular Society, Manchester
- Wada J, Ikeda T, Kamata K, Ebuoka M (1965) Oxygen hyperbaric treatment for carbon monoxide poisoning and severe burn in coal mine (Hokutanyubari) gas explosion. *Igakunoayumi (Japan)* 54-68
- Wang Z, Hasan R, Firwana B (2016) A systematic review and meta-analysis of tests to predict wound healing in diabetic foot. *Journal of Vascular Surgery* 63(2): 295-365
- Wang Y, Zeigler MM, Lam GK et al (2007) The role of the NADPH oxidase complex, p38 MAPK, and Akt in regulating human monocyte/macrophage survival. *Am J Respir Cell Mol Biol* 36: 68-77
- Wild T, Rahbarnia A, Kellner M et al (2010) Basics in nutrition and wound healing. *Nutrition* 26(9): 862-6
- Winfeld B (2014) Topical oxygen and hyperbaric oxygen therapy use and healing rates in diabetic foot ulcers. *Wounds* 26(5): E39-47
- Wollina U, Abdel-Naser MB, Mani R (2006) A review of the microcirculation in skin in patients with chronic venous insufficiency: the problem and the evidence available for therapeutic options. *Int J Lower Extrem Wounds* 5(3): 169-80
- World Union of Wound Healing Societies (2016) *Clinical report: Innovations in hard-to-heal wounds*. London: Wounds International
- Wounds UK (2016) *Best practice statement: Holistic management of venous leg ulceration*. London: Wounds UK
- Yarbrough OD, Behnke AR (1939) Treatment of compressed air illness utilizing oxygen. *J Indust Hyg Toxicol* 21: 213-18
- Yip WL (2015) Influence of oxygen on wound healing. *Int Wound J* 12: 620-24
- Yu J, Lu S, McLaren A-M, et al (2016) Topical oxygen therapy results in complete wound healing in diabetic foot ulcers. *J Vasc Surg* 24(6): 1536
- Zhao R, Liang H, Clarke E, et al (2016) Inflammation in chronic wounds. *Int J Molecular Sci* 17(12); pii:E2085

